

St. Catherine University

**SOPHIA**

---

Doctor of Physical Therapy Research Papers

Physical Therapy

---

4-2012

## Physical Therapy Management Following Femoroacetabular Impingement Correction and Acetabular Labral Repair: A Case Report

Jessica Walker  
*St. Catherine University*

Follow this and additional works at: [https://sophia.stkate.edu/dpt\\_papers](https://sophia.stkate.edu/dpt_papers)

---

### Recommended Citation

Walker, Jessica. (2012). Physical Therapy Management Following Femoroacetabular Impingement Correction and Acetabular Labral Repair: A Case Report. Retrieved from Sophia, the St. Catherine University repository website: [https://sophia.stkate.edu/dpt\\_papers/19](https://sophia.stkate.edu/dpt_papers/19)

This Research Project is brought to you for free and open access by the Physical Therapy at SOPHIA. It has been accepted for inclusion in Doctor of Physical Therapy Research Papers by an authorized administrator of SOPHIA. For more information, please contact [amshaw@stkate.edu](mailto:amshaw@stkate.edu).

PHYSICAL THERAPY MANAGEMENT FOLLOWING FEMOROACETABULAR  
IMPINGEMENT CORRECTION AND ACETABULAR LABRAL REPAIR:  
A CASE REPORT

BY: JESSICA WALKER

Doctor of Physical Therapy Program  
St. Catherine University

April 25, 2012

Research Advisor: Dr. Mary Weddle, PT, DSc

## ABSTRACT

**BACKGROUND AND PURPOSE:** Hip pain is a common complaint amongst active individuals. One cause of hip pain in the athletic population is femoroacetabular impingement (FAI). FAI is characterized by impingement between the head of the femur and the acetabulum of the hip joint due to structural abnormalities. Patients with FAI complain of hip pain that progressively worsens and eventually interferes with activities of daily living, such as ambulation. This case report describes physical therapy management following arthroscopic hip surgery for the treatment of FAI and acetabular labral tears in both inpatient and outpatient rehabilitation settings.

**CASE DESCRIPTION:** The patient was 15-year-old female high school student with a history of bilateral hip complaints who was actively involved in sporting activities. This case presents the rehabilitation following arthroscopic surgery of her right hip. Post-operative interventions included: lower extremity range of motion exercises, strengthening of core musculature as well as lower extremity musculature, and functional activities.

**OUTCOMES:** Following physical therapy intervention, the patient demonstrated improvements in function as measured by the Hip Dysfunction and Osteoarthritis Outcome Score (HOOS) and Hip Outcome Score (HOS). Her outcomes regarding return to sporting activities were limited secondary to bilateral hip complaints. Surgery on her left hip was scheduled two weeks after she was discharged from outpatient physical therapy for her right hip.

**DISCUSSION:** Surgical outcomes following arthroscopic hip surgery for correction of FAI are well reported, but limited literature is available describing physical therapy protocols and outcomes. This case describes the role of physical therapy intervention in facilitating this patient's return to prior level of function following arthroscopic hip surgery. Further research is needed in order to determine the effectiveness of physical therapy intervention and to determine best practices regarding post-operative protocols for patients with FAI.

The undersigned certify that they have read, and recommended approval of the research project entitled...

PHYSICAL THERAPY MANAGEMENT FOLLOWING FEMOROACETABULAR  
CORRECTION AND ACETABULAR LABRAL REPAIR: A CASE REPORT.

submitted by  
Jessica Walker

in partial fulfillment of the requirements for the Doctor of Physical Therapy Program

Primary Advisor Co-Advisor:



Date 7.29.12

## TABLE OF CONTENTS

CHAPTER I: INTRODUCTION/REVIEW OF RELATED LITERATURE	1
CHAPTER II: CASE DESCRIPTION	7
CHAPTER III: INTERVENTION	10
CHAPTER IV: OUTCOMES	12
CHAPTER V: DISCUSSION	15
REFERENCES	18

## APPENDICES:

APPENDIX A: INTERVENTION TABLE	20
APPENDIX B: CONSENT FORM	21

## INTRODUCTION/REVIEW OF RELATED LITERATURE

There are a number of well-recognized sources of hip pain in athletes. Hip and groin injuries account for 5-6% of all adult athletic injuries.<sup>1</sup> Common sources of hip pain include: myositis ossificans, piriformis syndrome, stress fractures, strains, and snapping hip syndrome.<sup>1</sup> More recently, femoroacetabular impingement (FAI) is being recognized as a source of hip pain in the younger athletic population.<sup>1,2,3</sup>

FAI occurs when anatomical abnormalities result in impingement between the femoral head and the acetabulum when the hip is in motion. The impingement limits hip range of motion, especially flexion and internal rotation.<sup>2,3,4,5</sup> Activities of daily living and sporting activities can cause repetitive microtrauma to either the acetabulum or femoral head and can result in damage to the acetabular labrum and/or the hip joint cartilage ultimately leading to hip osteoarthritis if the underlying cause of FAI is not addressed.<sup>1,3,5,6</sup>

### *Types of FAI*

There are two distinguishable types of FAI: Cam and pincer.<sup>1-7</sup> The two types differ depending on whether the abnormality exists in the femoral head or the femoral acetabulum. Cam impingement is caused by an aspherical portion of the femoral head-neck junction.<sup>1-4,6</sup> The region of impingement usually occurs on the anterior-lateral region of the femoral head-neck junction.<sup>5</sup> During hip flexion motions the superior-anterior portion of the acetabular cartilage is sheared at the labral/cartilage junction.<sup>5</sup> Pincer impingement involves the acetabular cause of FAI and is due to focal or general overcoverage of the femoral head.<sup>1-6</sup> In this case, as the hip is flexed the neck of the

femur contacts the acetabulum and the labrum repeatedly, resulting in damage to the labrum or the acetabulum. Also associated with the pincer type deformity is a contrecoup injury. This involves injury to the posterior aspect of the acetabulum which occurs after the femoral head makes contact with the anterior portion of acetabulum and is then forced into a posterior direction.<sup>5</sup> Table 1 compares the characteristics of the two types of FAI. Interestingly, the most common deformity is a mixed cam and pincer pathology.<sup>1,3,4</sup>

**Table 1.**

Characteristics of the Two Types of FAI (adapted from Tannast et al 2007)

<b>Criteria</b>	<b>Cam Impingement</b>	<b>Pincer Impingement</b>
Cause	Aspherical head	Focal or general over-coverage
Mechanism	Jamming of aspherical head into acetabulum	Linear contact between over-covering rim and head-neck junction
Sex Distribution (M:F)	14:1	1:3
Average age (range) (y)	32 (21-51)	40 (40-57)
<b>Criteria</b>	<b>Cam Impingement</b>	<b>Pincer Impingement</b>
Typical location of cartilage damage	11-to3-o'clock position	Circumferential with coutercoup
Average depth of cartilage damage (mm)	11	4

#### *Clinical Presentation Associated with FAI*

The onset of FAI in the younger athletic population is usually insidious and is more common in adolescent females than males.<sup>1,5</sup> Athletes, especially dancers and hockey players are particularly at risk for these symptoms because these sports place high demand on the hip joint with repetitive hip flexion and internal rotation positions.<sup>4</sup> It is at the extremes of flexion and internal rotation that impingement between the acetabular labrum and the cartilage of the hip occurs.<sup>4</sup> Other sporting activities in which excessive

hip flexion and internal rotation occurs include tennis, martial arts, weight lifting, soccer, and horseback riding.<sup>1</sup>

The most common subjective complaint from a patient with FAI is that of anterior groin pain.<sup>1,5,7</sup> Occasionally the pain may also be described as buttock pain that does not radiate past the knee.<sup>5</sup> Further pain descriptors may include: pain with prolonged sitting, pain with prolonged walking, pain with donning and doffing shoes and socks, and pain with athletic activities.<sup>5,7</sup> Associated with this groin pain is a decrease in activity level, and frequently, complete cessation of sporting activities secondary to increased pain. In addition to pain, these patients will report a loss of hip ROM, with the greatest losses in flexion and internal rotation, which becomes a limiting factor in an athlete's performance.<sup>1</sup> A study by Sink et al reported the average hip flexion range of motion to be 95 degrees and average hip internal rotation to be 15 degrees on the symptomatic hip of a patient diagnosed with FAI.<sup>5</sup>

Physical exam often reveals a positive anterior impingement test.<sup>1, 7-9</sup> For the anterior impingement test the patient lies supine, the examiner passively flexes the patient's hip to 90 degrees, and then adducts and internally rotates the hip. In this position, the examiner is forcing the anterior portion of the femoral neck into the anterosuperior acetabulum, thereby re-creating the impingement.<sup>1,5,8,9</sup> A positive test occurs when the patient complains of pain in this position.<sup>1,8,9</sup>

#### *Diagnosis of FAI*

The diagnosis of FAI made by an orthopedic physician is based on information from the patient's subjective history, physical examination findings, and diagnostic



imaging findings. The use of radiographs, such as x-rays, CT scans, and MRIs, is standard procedure in forming the diagnosis of FAI.<sup>2,5</sup> The alpha angle can be obtained from an axial view radiograph of the hip joint and used in making the diagnosis of FAI. The alpha angle represents the insufficient anterolateral head-neck offset as well as femoral neck asphericity and therefore determines the degree of impingement.<sup>2</sup> The angle is formed by measuring the lines between the midpoint of the femoral neck to the center of the femoral head and from the center of the femoral head to where the head of the femur begins to deviate from its spherical shape.<sup>10</sup> While normative data does not exist for alpha angles, the alpha angle in an asymptomatic hip is 42° on average.<sup>10</sup> An increased alpha angle has been shown to correlate with symptoms of femoral acetabular impingement.<sup>2</sup> The larger the alpha angle, the greater the areas of acetabular cartilage damage, labral injury, and loss of range of motion.<sup>10</sup>

#### *Acetabular Labral Tears*

A common finding associated with FAI is acetabular labral damage as a secondary result of shearing forces due to the abutment of the femoral head and acetabular labrum when the hip is in motion.<sup>11</sup> The acetabular labrum forms a fibrocartilagenous rim that runs circumferentially around the of the acetabulum.<sup>1</sup> The labrum does not form a complete circle around the acetabulum; the transverse ligament of the acetabulum completes the inferior edge of the labrum over the acetabular notch.<sup>1,8</sup> The cross-sectional area of the labrum is usually triangular; however, in some individuals the labrum is not triangular, but rather round, irregular, or flattened.<sup>1,8</sup> The cross-sectional shape does not appear to be associated with the incidence of hip pain.<sup>8</sup> The anterior

portion of the labrum is wider and thinner than the thicker posterior region of the labrum.<sup>8</sup> For the most part, the acetabular labrum is believed to be avascular, with only some blood vessels penetrating into the outer one-third of the acetabular labrum.<sup>8</sup> The acetabular labrum is innervated by a variety of nerve endings.<sup>8</sup>

The function of the labrum is to create a suction seal for the hip joint. This sealing mechanism of the acetabular labrum decreases the contact stresses between the acetabulum and the cartilage by distributing the load throughout the acetabular cartilage.<sup>8</sup> This seal can be compromised by a tear in the labrum, thereby increasing the stresses placed on the hip joint and possibly leading to joint degeneration.<sup>8</sup>

#### *Intervention for FAI*

Treatment for FAI commonly begins with conservative measures consisting of physical therapy and activity modification. The goal of physical therapy management is to decrease the patient's hip pain and to protect the hip joint by altering activities of daily living.<sup>12</sup> The patient is encouraged to engage in "relative rest" which includes decreasing the amount of time spent in activities that provoke hip pain and avoiding excessive physical activity.<sup>5,12</sup> Physical therapy intervention strategies include stretching to improve hip range of motion as well as strengthening of core and hip musculature.<sup>5,12,13</sup> Patients with FAI are also provided with education to avoid end range hip flexion and internal rotation during both static and dynamic postures in order to prevent further damage to the hip joint.<sup>12</sup>

Often times conservative treatment is unsuccessful because patients diagnosed with FAI are very athletic and have difficulty reducing their activity level until the pain

becomes so great that they cease participation and the underlying cause of FAI, the structural abnormalities, cannot be fixed with conservative measures. The recent standard in treating FAI that does not respond to conservative treatment involves surgical hip arthroscopy with the goal of surgery to decrease the contact between the acetabulum and the femoral head by improving joint clearance and allowing for greater pain-free hip ROM.<sup>6</sup>

Postoperative management of FAI is highly individualized to each individual surgeon's protocol. Postoperative guidelines often include restrictions to hip range of motion and weight bearing in order to protect the surgical site.<sup>5</sup> Range of motion exercises are performed immediately following surgery to prevent the formation of scar tissue adhesions and in order to facilitate return of hip range of motion.<sup>5</sup> To promote early range of motion, a continuous passive motion machine is often utilized.<sup>5</sup> De-rotation boots may be recommended to limit hip internal and external rotation. In addition, a hip brace may be used during ambulation to decrease hip abduction and extension range of motion.<sup>5</sup> Lastly, post-operative physical therapy is utilized to promote return to prior level of function, which often times involves return to high level sporting activities.<sup>4</sup>

#### *Purpose*

Current research emphasizes surgical outcomes in the treatment of FAI; however, little research exists on physical therapy management and outcomes for a patient with FAI and associated pathologies. The purpose of this case report is to describe the physical therapy interventions and outcomes for a patient with FAI.

## CASE DESCRIPTION

The patient was a 15-year-old female high school student who underwent right hip arthroscopy, cam resection, and labral repair secondary to FAI. The patient had the same surgical procedure performed on her left hip three months after her right hip surgery; the primary focus of this case report will be on her right hip. The patient had a two and a half year history of bilateral hip complaints. She reported her right hip pain was worse than her left hip pain. Her pain was located in her right groin and buttock regions. She could not identify one incident that triggered the onset of her hip pain, but instead reported that the pain gradually worsened over time. She was an active adolescent involved in dance, softball, tennis, and color guard. Review of her medical chart revealed no past surgical history. Significant past medical history included treatment for depression. At the initial physical therapy evaluation informed consent was obtained from the patient and her parents to participate in this case report. Information about this patient's hospital visits and outpatient therapy visits were obtained from a medical chart review in a manner compliant with the Health Insurance Portability and Accountability Act.

Prior to her right hip surgery, the patient received over three months of outpatient physical therapy. She had to decrease her activity level dramatically in order to find pain relief during this time. She also used oral pain medication as needed in order to decrease her pain. The source of her hip pain was not clearly diagnosed and she reported seeing multiple physicians who gave her differing diagnoses. The patient was eventually referred to an orthopedic surgeon after physical therapy did little to resolve her symptoms

and a diagnosis of bilateral FAI and acetabular labral tears was made. Imaging (x-ray and MRI) confirmed the diagnosis of bilateral labral tears with cam impingement and early cartilage changes at the anterior acetabular rim. The alpha angle was measured from the x-ray and found to be greater than 65 degrees on a 45-degree Dunn view (an anterior-posterior view with the hip in neutral rotation with 45 degrees of flexion and 20 degrees of abduction). The risks and benefits of treatment options were discussed with the patient and her parents and they chose to proceed with hip arthroscopy, beginning with the right hip and followed a few months later by the left hip.

#### *Exam Findings*

The patient's surgical and physical therapy pre-operative examination revealed decreased hip ROM in all planes, with the greatest loss in flexion and internal rotation motions. She had a positive impingement test, Trendelenberg test, straight leg raise, and FABER test. She also demonstrated an antalgic gait pattern. Additional exam data included information obtained from the Hip Dysfunction and Osteoarthritis Outcome Score (HOOS) and the Hip Outcome Score (HOS). The HOOS is intended for use in patients that have a hip disability with or without hip osteoarthritis. It is a self-report outcome measure consisting of 40 items and it has five dimensions, which are scored separately. A lower score on the HOOS indicates a perceived lower level of function. This patient scored particularly low on the sports and quality of life dimensions. The HOOS has not been validated for the use in a younger population. However, an outcome measure that is valid, reliable and responsive in this population is the HOS.<sup>14,15</sup> The HOS is a self-report questionnaire divided into an activity of daily living and sports subscale.

On both subscales, a higher score indicates a higher level of physical functioning. The significant participation restrictions found in the HOOS were reinforced with the use of the HOS. The patient's scores on these outcome measures are shown in Tables 2 and 3.

**Table 2.** Baseline HOOS Scores

<b>Dimension</b>	<b>Score out of 100</b>
Pain	57.5
Symptoms	55
Activities of Daily Living	65
Sport	18.75
Quality of Life	19

**Table 3.** Baseline HOS Scores

<b>Subscale</b>	<b>Score</b>
Activities of Daily Living	24/68
Sports	9/36

After receiving the diagnosis of FAI and prior to her surgery, the patient attended pre-operative outpatient physical therapy one time a week for four weeks. The goals of these pre-operative physical therapy sessions were to increase strength in hip musculature, improve proprioception, and provide neurological re-education. The patient was also educated on the postoperative rehabilitation protocol and expectations.

#### *Clinical Impression and Plan of Care*

The patient's physical therapy diagnosis was impaired joint mobility, motor function, muscle performance, and range of motion associated with bony or soft tissue surgery (Guide to Physical Therapist Practice 4I). She had difficulty with transfers, gait, and stairs secondary to pain, decreased ROM, decreased strength, and weight bearing restrictions. The potential to achieve her physical therapy goals was good secondary to her motivation, support from her family, and her prior level of function. Her potential to

return to high level sporting activities after surgery on the right hip was limited due to the bilateral nature of her symptoms.

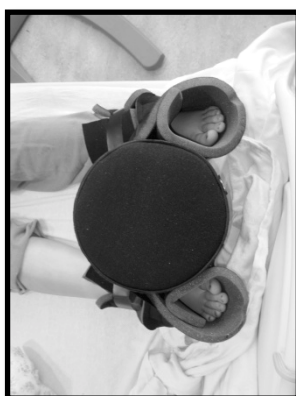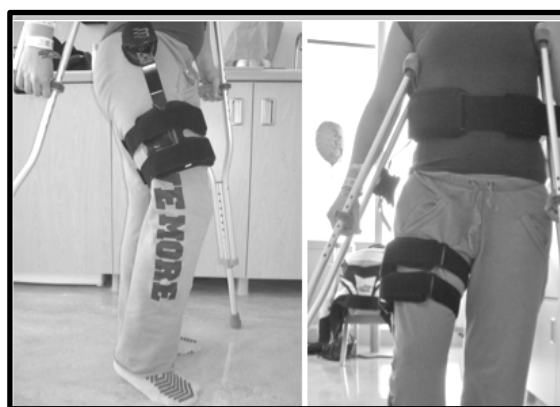The patient's plan of care included physical therapy in the acute care and outpatient settings. In acute care, the patient was seen in physical therapy for two visits, one the evening of her surgery and the 2<sup>nd</sup> the following morning before discharge. The patient's acute care goals included: independence with transfers, gait, and stairs in order to return home upon discharge. The prognosis for her acute care stay was good and estimated to be one day. Recommendations were made to receive outpatient physical therapy in order to facilitate return to prior level of function. The plan of care in the outpatient setting included physical therapy visits two times a week for four weeks, decreasing to one time a week for the next four weeks, and one time every other week for the following eight weeks. Her outpatient goals included: increasing hip strength and ROM, improving her gait pattern, and facilitating the return to sporting activities.

## **INTERVENTION**

Physical therapy management for a patient with FAI in the acute care setting involved extensive education to the patient and family regarding the use of the post-operative equipment, weight bearing status, ROM restrictions, and initial home exercise program. Protocol following this type of arthroscopic hip surgery involved the use of three pieces of equipment (Figures 1 and 2): a continuous passive motion (CPM) machine, Bledsoe Philippon post-operative hip brace, and de-rotation boots. All of these pieces of equipment were used for 2 weeks (Table 4).

**Table 4.** Description and Purpose of Post-operative Equipment Used.

Equipment	Purpose/Description
CPM machine	<ul style="list-style-type: none"> <li>• Avoid capsular adhesion, decrease pain, decrease stiffness</li> <li>• Used for 4-6 hours/day (non-continuous)</li> <li>• Initially set from 0-90°, progressed as tolerated to achieve 120°</li> </ul>
Bledsoe Phillipon post-op hip brace	<ul style="list-style-type: none"> <li>• Prevent sagittal plane movement of the hip joint (allows 0° to 90° hip flexion)</li> <li>• Prevent excessive abduction</li> <li>• Worn at all times when out of bed</li> </ul>
De-rotation boots	<ul style="list-style-type: none"> <li>• Prevent excessive external rotation</li> <li>• Patient's feet strapped into a neutral position with foam centerpiece to maintain proper alignment</li> <li>• Worn at all times when in bed and not using the CPM machine</li> </ul>

**Figure 1.** De-rotation boots.**Figure 2.** (a) Lateral view of Bledsoe Phillipon hip brace. (b) Anterior view of Bledsoe Phillipon hip brace.

According to the physician's protocol, rehabilitation was divided into three phases (intervention details provided in Appendix A). Goals for phase one included: protection of the repaired tissues; decreasing pain, swelling, and inflammation; and restoring ROM within the given precautions (movements to avoid: hip external rotation, hip extension, excessive hip abduction, and adduction). Intervention strategies utilized in this phase included passive and active ROM, the use of a stationary bike without resistance and



joint mobilization techniques. Goals for phase two included: increasing muscular strength and muscular endurance with emphasis on the patient's core hip and other lower extremity musculature. Goals for phase three included optimizing neuromuscular control, improving balance, and improving proprioception. Advanced strengthening and sport specific activities were utilized in order to accomplish these goals.

## **OUTCOMES**

At 2 weeks after surgery the patient reported that her right hip felt "normal". At this time she wanted to run, but was advised against doing so since it had been less than one month since surgery and doing so would be outside of the protocol guidelines. She reported and demonstrated compliance with her HEP as noted in her ability to independently perform all exercises when prompted to do so, with minimal cueing to correct technique. Also, at this time her primary complaint involved stiffness and pain after sitting in a car for greater than one hour. Her non-operative (left) hip contributed more to her pain than her right hip. She was able to discontinue the use of the bilateral axillary crutches during ambulation and demonstrated a normal gait pattern with minimal right hip pain. The right hip pain could be decreased with verbal cues to activate her gluteus maximum at terminal right hip extension to decrease activation of her hip flexors, which was hypothesized to be the cause of her anterior right hip pain. Due to her progress at this point, frequency of PT was decreased from twice per week to once per week for two weeks.

In general, the patient progressed a little faster than expected for patients following arthroscopic hip surgery for treatment of FAI and therefore began stage two exercises sooner than similar patient after hip arthroscopy. After her sixth visit she began to demonstrate inconsistent attendance with many of her physical therapy visits. At 11 weeks after surgery the patient was able to participate in a trip to an amusement park and ambulated the entire day without hip complaints. The patient was also able to help her family move. She denied any hip pain on the right, but reported her left hip was painful and sore and that she was ready for surgery on her left hip the following week.

Her results from the HOOS and HOS are represented below (Figures 3, 4, 5). The patient made improvements through week 11 in all five categories of the HOOS. However, the patient achieved mixed results between the two subscales of the HOS. On the ADL subscale the patient increased her score from before surgery to week five. Given the minimal clinically important difference (MCID) of nine points on the ADL subscale, the patient demonstrated a clinically significant change from 24 to 50 points.<sup>14,15</sup> Pain was a limiting factor prior to surgery and these results suggest the patient had a greater level of functioning in which she was pain free. In contrast, the patient's score on the sports subscale at five weeks demonstrates a clinically significant decrease given a MCID of six points on the sports subscale.<sup>14,15</sup> Of note is how low both scores are on the sports subscale. Perhaps the patient perceived her functioning to be lower at five weeks because of the recent surgery and the clear restrictions she was given on higher-level activities. Prior to surgery, when she initially completed the scale she may have been able to push through the pain to complete these higher-level activities.

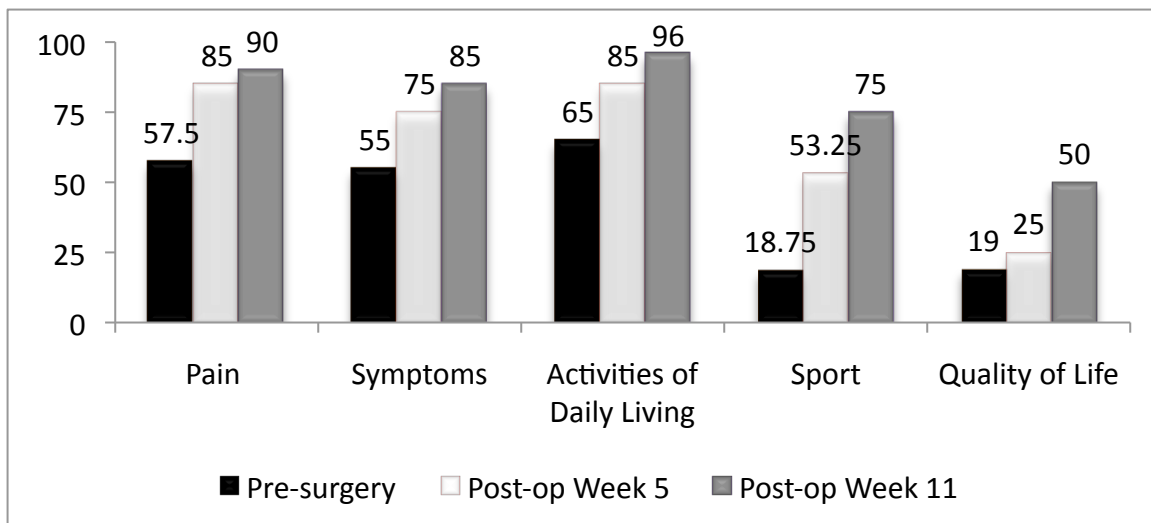


Figure 3. HOOS scores from before surgery to week 11.

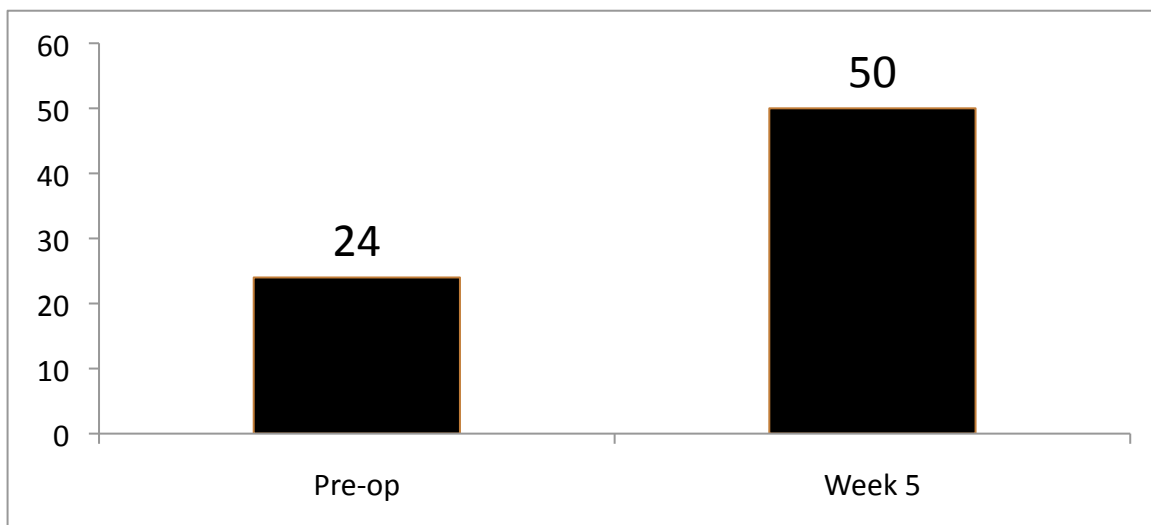


Figure 4. Hip Outcome Score (HOS) – ADL subscale

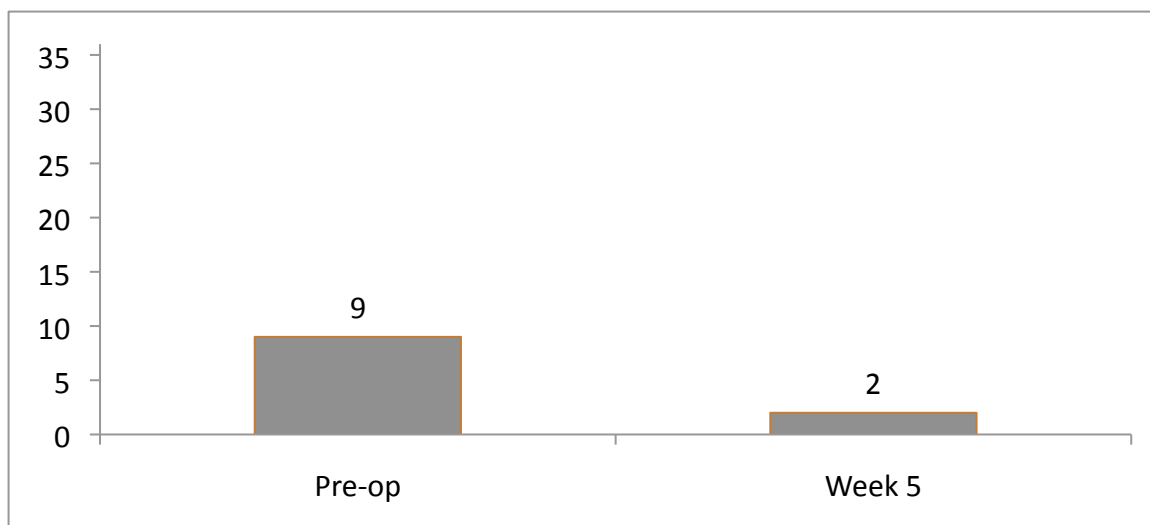


Figure 5. Hip Outcome Score (HOS) – Sports subscale

## DISCUSSION

Surgical outcomes following arthroscopic hip surgery for FAI and labral tears are well reported in the literature; however, there is limited information describing physical therapy intervention strategies for rehabilitation following these surgeries. This case report described the role of physical therapy in facilitating a 15-year-old female's return to sporting activities after labral repair secondary to FAI. The patient described demonstrated improvement in her HOOS scores and HOS scores from pre-surgery to 11 weeks post-surgery. Following surgery and physical therapy, her right lower extremity was pain free while performing activities of daily living, although her ability to return to her sporting activities remained limited by her left hip pain.

This case report adds to the limited available literature describing physical therapy rehabilitation for patients with this specific hip impairment. The rehabilitation protocol utilized in this case report was based on the protocol described by Stalzer et al.<sup>16</sup>

This protocol incorporated principles of tissue healing and protection of the structures to allow healing and prevent excessive stress on the tissues. The protocol used in this case report utilized similar phases that emphasized a progression from improving ROM and strength to addressing functional limitations and incorporating sport specific activities.

This case demonstrates a unique role for physical therapists when working with this patient population. Physical therapists can aid in early detection through the use of differential diagnostic skills, which may decrease the time it takes for a patient to be referred to a surgeon for diagnosis. The patient in this case experienced symptoms and functional limitations for two and a half years prior to receiving the diagnosis of FAI. Physical therapists can also increase awareness of this relatively new diagnosis. This case also demonstrates the role that the physical therapist plays as a part of an inter-professional team. A close collaboration between the physical therapist and the physician is essential, as occurred in this case report, in order to determine the best practices to be used in the protocol. Lastly, physical therapists play a role in educating this highly motivated athletic population about protecting the surgical site. Physical therapists need to continue to remind these patients to avoid returning to activity too soon despite feeling good early on in the rehabilitation process, as occurred with this patient as she was ready to attempt running at two weeks post-op, but was advised against doing so. After discharge from the hospital, physical therapists can also provide follow-up care about the elaborate equipment use.

This case report was limited by several factors. First, due to the patient's inconsistent attendance at scheduled outpatient physical therapy visits, information

regarding outcomes was not collected at regular intervals as originally planned. Second, the author of this case report was not the primary treating PT in the outpatient setting and had to rely on notes written by the PT who continued to see the patient as an outpatient.

One valuable contribution of case reports is the identification of questions that warrant further research. Research using a large number of subjects could determine not only the effectiveness of a physical therapy rehabilitation program, but also seek to determine the best practice guidelines when working with the post-operative hip arthroscopy patient population. In addition to using a large patient population, future research involving the use of aerobic endurance training as a part of the plan of care would be interesting to investigate since many of these patients are athletes and aerobic endurance is an important part of the athletes' overall performance. Lastly, it has been hypothesized that this surgical procedure decreases the risk for osteoarthritis and long-term studies are needed to determine if these patients do in fact have a decreased incidence of osteoarthritis.

## REFERENCES

1. Keogh MJ, Batt ME. A review of femoroacetabular impingement in athletes. *Sports Med.* 2008;38:863-878.
2. Rakhra KS, Sheikh AM, Allen D, Beaulé PE. Comparison of MRI alpha angle measurement planes in femoroacetabular impingement. *Clin Orthop Relat Res.* 2009;467:660-665.
3. Tannast M, Siebenrock KA, Anderson SE. Femoroacetabular impingement: radiographic diagnosis-what the radiologist should know. *Am J Roentgenol.* 2007;188:1540-1552.
4. Philippon M, Schenker M, Briggs K, Kuppersmith D. Femoroacetabular impingement in 45 professional athletes: associated pathologies and return to sport following arthroscopic decompression. *Knee Surg Sports Traumatol Arthrosc.* 2007;15:908-914.
5. Sink EL, Gralla J, Ryba A, Dayton M. Clinical presentation of femoroacetabular impingement in adolescents. *J Pediatr Orthop.* 2008;28:806-811.
6. Philippon MJ, Schenker ML. Arthroscopy for the treatment of femoroacetabular impingement in the athlete. *Clin Sports Med.* 2006;25:299-308.
7. Philippon MJ, Maxwell RB, Johnston TL, Schneker M, Briggs KK. Clinical presentation of femoroacetabular impingement. *Knee Surg Sports Traumatol Arthrosc.* 2007;15:1041-1047.
8. Lewis CL, Sharmann SA. Acetabular labral tears. *Phys Ther.* 2006;86:110-121.
9. Philippon MJ, Briggs KK, Yen YM, Kuppersmith DA. Outcomes following hip arthroscopy for femoroacetabular impingement with associated chondrolabral dysfunction. *J Bone Joint Surg.* 2008;91-B:16-23.
10. Johnston TL, Schenker ML, Briggs KK, Philippon MJ. Relationship between offset angle alpha and hip chondral injury femoroacetabular impingement. *Arthroscopy.* 2006;24:669-675.
11. Jaber FM, Parvizi J. Hip pain in young adults: femoroacetabular impingement. *J Athroplasty.* 2007;22:37-43.

12. Emara K, Samir W, Motasem H, Ghafar KA. Conservative treatment for mild femoroacetabular impingement. *Journal of Orthopaedic Surgery*. 2011;19:41-45.
13. Yazbek PM, Ovanessian V, Martin RL, and Fukuda TY. Nonsurgical treatment of acetabular labrum tears: a case series. *J Orthop Sports Phys Ther*. 2011;41:346-353.
14. Martin RL and Philippon MJ. Evidence for validity for the Hip Outcome Score in hip arthroscopy. *Arthroscopy*. 2007;23:822-826.
15. Martin RL and Philippon MJ. Evidence for reliability and responsiveness for the Hip Outcome Score. *Arthroscopy*. 2008;24:676-682.
16. Stalzer S, Wahoff M, Scanlan M. Rehabilitation following hip arthroscopy. *Clin Sports Med*. 2006;25:337-357.



## APPENDIX A: INTERVENTION TABLE

	Phase 1	Phase 2	Phase 3
<b>ROM</b>	<ul style="list-style-type: none"> <li>Passive hip circumduction @ 30° and 60° hip flexion</li> <li>Passive supine hamstring stretch</li> <li>Passive prone quad stretch</li> <li>Sidelying piriformis stretch</li> <li>Passive hip flexion</li> <li>Stationary bike – no resistance</li> <li>Passive hip abduction</li> <li>Quadruped hip flexion stretch</li> </ul> Joint mobilization	<ul style="list-style-type: none"> <li>Standing active hip internal rotation</li> <li>Progressive hip external rotation</li> </ul>	
<b>Gait</b>	<ul style="list-style-type: none"> <li>Education on weight bearing status</li> <li>Crutch training</li> </ul>	<ul style="list-style-type: none"> <li>Correction of gait abnormalities post crutch use</li> </ul>	<ul style="list-style-type: none"> <li>“Flamingo walking” gait drill</li> </ul>
<b>Strength</b>	<ul style="list-style-type: none"> <li>Supine active hip internal rotation</li> </ul>	<ul style="list-style-type: none"> <li>Transverse abdominus isometric contraction</li> <li>Lower abdominal/hip flexor marching</li> <li>Eccentric hip flexion leg lowering</li> <li>Sidelying hip external rotation</li> <li>Bent over hip extension</li> <li>Sidelying hip abduction</li> <li>Prone hip extension</li> <li>Hamstring curls with physioball</li> <li>Sidelying hip internal rotation + adduction</li> <li>Standing resisted hip adduction</li> <li>Hip abduction/adduction with physioball</li> <li>Bridging series</li> <li>Prone plank series</li> </ul>	<ul style="list-style-type: none"> <li>Side plank series</li> <li>Bilateral leg squat</li> <li>Unilateral squat</li> <li>Forward/side lung</li> <li>Resisted side stepping</li> <li>BOSU squatting &amp; lunging</li> <li>Squat re-training</li> </ul>
<b>Balance/ Proprioception</b>		<ul style="list-style-type: none"> <li>Prone hip pendulums</li> </ul>	<ul style="list-style-type: none"> <li>Leg lifting in single leg balance</li> <li>Resisted single leg lifting in single leg stance</li> <li>BOSU hip proprioception</li> <li>“Slow motion runner”</li> <li>“Apple picking drill”</li> </ul>

## APPENDIX B: CONSENT FORM

**St. Catherine University Doctor of Physical Therapy Program****Case Report – Information and Consent Form****Introduction:**

You are invited to be the subject of a case report assignment to be written by \_\_\_\_\_, Doctor of Physical Therapy graduate student from St. Catherine University, under the supervision of John Schmitt, PT, PhD, Doctor of Physical Therapy program faculty member, and \_\_\_\_\_, the student's clinical instructor/s. You were selected as a possible subject for this case report assignment because your course of physical therapy care would be of interest to physical therapist students and physical therapists. Please read this form and ask questions before you agree to be the subject of this case report.

**Background Information:**

The purpose for his case report assignment is to describe the physical therapy care you are receiving and how you response to the care you are receiving at

---

(name and address of facility)

This case report assignment will help others better understand how physical therapy may help other people like you.

**Procedures:**

Your decision about participation will not affect your physical therapy care in any way. If you decide to participate, your physical therapy care will proceed just as it would if you were to decide not to participate, If you decide to participate, you may choose whether or not you will allow the following:

1. Whether your photograph can be taken and use in public presentation of this case report assignment;
2. Whether what you say can be quoted direction in the case report assignment.

This case report assignment will be read by the DPT faculty members. This case report assignment may be read by the physical therapist/s supervision the student at this facility. The case report assignment will be present to other students and faculty as the St. Catherine University Doctor of Physical Therapy Program. The case report assignment may be also be presented at a professional meeting locally or nationally.

**Risks and Benefits:**

There are no risks or benefits to you for participating in this case report assignment.

**Confidentiality:**

Any information obtained in connection with this case report assignment that could identify you will be disclosed only with your permission. Unless stated otherwise, your name, or names of your members, will not be used in any way in the case report.

**Voluntary nature of this case report:**

Participation in this case report assignment is voluntary. Your decision whether or not to participate will not affect your future relations with St. Catherine University, or with the facility at which you are receiving physical therapy. If you decide to participate, you are free to discontinue participation at any time without affecting these relationships.

**Contacts and questions:**

You are encouraged to ask the student or the physical therapists supervising the student any questions about this case report assignment at any time. You may also contact John Schmitt, DPT Program Faculty, if you have questions at any time (see contact information below). You may keep a copy of this consent form for your records.

**Statement of Consent:**

You are making a decision whether or not to participate in this case report assignment. Your signature indicates that you have read this information and your questions have been answered. Even after signing this form, please know that you may discontinue your participation in this case report assignment at any time.

I agree to participate in this case report assignment. Yes \_\_\_\_\_ No \_\_\_\_\_

I agree to being quoted directly in this case report assignment Yes \_\_\_\_\_ No \_\_\_\_\_

I agree to being photographed and having the photographs in the public presentation and/or publication of this case report assignment. Yes \_\_\_\_\_ No \_\_\_\_\_

---

Signature of subject indicating assent to participate Date

---

Signature of parent indicating consent to participate Date

---

DPT student's signature Date

Faculty member supervising the student:

John Schmitt, PhD, PT  
Assistant Professor  
Doctor of Physical Therapy Program

St. Catherine University  
601 25<sup>th</sup> Avenue South  
Minneapolis, MN 55454  
Phone: 651-690-7739